

Adnexal torsion in a patient with Müllerian agenesis undergoing ovarian stimulation: a case report

Erika P. New, MD, MPH,¹ Adrienne R. Mallen, MD,¹ Abigail C. Mancuso, MD,² Bradley J. Van Voorhis, MD²

Keywords: Adnexal torsion, Mayer-Rokitansky-Kuster-Hauser syndrome, Müllerian agenesis, oophoropexy, ovarian torsion, uterovaginal agenesis

Abstract

Background: As assisted reproductive technologies become increasingly available to patients, more women with Müllerian agenesis may undergo ovarian stimulation and oocyte retrieval to have genetically-related offspring. The risk of ovarian torsion is increased in patients utilizing assisted reproductive technologies compared to patients who do not undergo these treatments.

Case: A 25-year-old G0 with Mayer-Rokitansky-Kuster-Hauser syndrome presented to the emergency room two days after oocyte retrieval with an acute abdomen. During laparoscopy, she was found to have torsion of her left ovary.

Summary and Conclusion: As more young women with Müllerian agenesis present for fertility treatment, this anatomically unique patient cohort may be at an especially high risk for ovarian torsion. Physicians should recognize this risk and counsel their patients on this risk when discussing fertility options in patients with Müllerian agenesis.

¹Department of Obstetrics and Gynecology, University of South Florida, Tampa, FL

²Department of Obstetrics and Gynecology, University of Iowa Hospitals and Clinics, Iowa City, IA

Introduction

While women with Mayer-Rokitansky-Kuster-Hauser syndrome typically have congenital absence of the uterus, cervix and even part of the vagina, they do have functional ovaries.¹ Previously, the only option for reproduction for young women with Mayer-Rokitansky-Kuster-Hauser syndrome was adoption. Now with the increasing availability of assisted reproductive technologies, more women may choose to undergo ovarian stimulation and oocyte retrieval for in vitro fertilization with gestational surrogacy to have genetically-related offspring. As confirmed in a recent systematic review, women with

Please cite this paper as: New EP, Mallen AR, Mancuso AC, Van Voorhis BJ. Adnexal torsion in a patient with Müllerian agenesis undergoing ovarian stimulation: a case report. *Proc Obstet Gynecol.* 2018;8(2): Article 3 [6 p.]. Available from: <http://ir.uiowa.edu/pog/> Free full text article

Corresponding author: Bradley J. Van Voorhis, MD, Department of Obstetrics and Gynecology, Reproductive Endocrinology and Infertility Division, 200 Hawkins Drive, 31335 PFP, Iowa City, IA 52242. Phone: (319) 356- 4536. Email: brad-van-voorhis@uiowa.edu

Financial Disclosure: The authors report no conflict of interest.

Copyright: © 2018 New et al. This is an open-access article distributed under the terms of the Creative Commons Attribution License, which permits unrestricted use, distribution, and reproduction in any medium, provided the original author and source are credited.

Müllerian agenesis have utilized in vitro fertilization for assisted reproduction.² The risk of ovarian torsion is increased in patients undergoing assisted reproduction compared to patients who do not undergo this treatment; one study showed an absolute incidence of 0.8% in in vitro fertilization (IVF) cycles and an even higher incidence of 7.5% in patients with ovarian hyperstimulation syndrome.³ Our patient with Mayer-Rokitansky-Kuster-Hauser syndrome developed ovarian torsion after undergoing ovarian stimulation and oocyte retrieval in the setting of mild ovarian hyperstimulation syndrome.

Case

The patient is a 25-year-old G0 female with Mayer-Rokitansky-Kuster-Hauser syndrome who presented to our Reproductive Endocrinology and Infertility division to discuss IVF for possible surrogacy. Her past medical history included evaluation for primary amenorrhea at age 15, with pelvic exam revealing a blind-ending vagina and transvaginal ultrasound demonstrating absence of a uterus with normal appearing ovaries. She had a normal, female (46XX) karyotype as part of her work-up. She had no history of abdominopelvic surgery, and her family and social history were unremarkable. She took no medications including hormones. On examination, her body mass index was 20 and she had a blind-ending, functional vagina without need for dilators.

She elected to proceed with IVF and oocyte retrieval. An antagonist protocol was utilized. She was triggered with a combination of Leuprolide (Lupron) with a dose of 2 milligrams and low-dose

human chorionic gonadotropin (hCG) with a dose of 1500 units. This protocol is commonly used in our practice to reduce ovarian hyperstimulation syndrome rates. A transvaginal oocyte retrieval was performed. The procedure was uncomplicated and resulted in 37 eggs and 20 embryos following fertilization by intracytoplasmic sperm injection (ICSI). The embryos were biopsied for preimplantation genetic screening and 6 euploid embryos were cryopreserved for future use with a gestational carrier.

On the evening after the oocyte retrieval, the patient presented to a local emergency room with diffuse lower abdominal pain. Her vital signs on arrival to the emergency room were: blood pressure 106/65, pulse 70, temperature 37.1 degrees Celsius, respiratory rate 18 breaths/minute and oxygen saturation of 100% on room air. Complete blood count, comprehensive metabolic panel and urinalysis were within normal limits. Her abdominal examination was benign with no rebound tenderness. Transvaginal ultrasound demonstrated enlarged ovaries with blood flow noted bilaterally by Doppler study with some free fluid in the pelvis. She was discharged home and presented to our clinic the following day for continued abdominal pain. She was found to have abdominal distention with no rebound tenderness or involuntary guarding on abdominal examination. A complete blood count and basic metabolic panel were drawn and within normal limits. Transvaginal ultrasound examination revealed enlarged ovaries bilaterally with the greatest dimension of approximately 11 cm on each side and a moderate

amount of free fluid in the cul-de-sac. On color Doppler studies, ovarian blood flow was noted bilaterally. The patient was diagnosed with mild ovarian hyperstimulation syndrome based on her clinical features, normal laboratory values and ultrasound findings and discharged home.

Later that evening, the patient presented to our emergency room, now roughly 48 hours after the oocyte retrieval, for acute worsening of her abdominal pain. The pain was in the left lower quadrant, and now described as severe, constant and radiating to her vagina. Her vital signs on arrival to the emergency room were: blood pressure 128/64, pulse 114, temperature 38.1 degrees Celsius, respiratory rate 18 breaths/minute and oxygen saturation of 100% on room air. On physical examination, she had rebound tenderness and involuntary guarding. The decision was made to proceed with emergent laparoscopy due to the strong suspicion for ovarian

torsion. The patient was taken to the operating room immediately after decision was made and informed consent was signed. A pelvic examination was performed under anesthesia and confirmed a blind-ending vagina along with bilateral adnexal fullness. Initial laparoscopic findings included grossly enlarged ovaries bilaterally consistent with recent oocyte retrieval (Figure 1). The left ovary was dusky in color and larger than the right, measuring approximately 12 cm x 10 cm. The left ovary was twisted 360 degrees on the infundibulopelvic ligament and it was successfully reduced using blunt probes with a gradual return of normal coloration allowing preservation of this ovary. Small uterine remnants were noted bilaterally with short round ligaments and very attenuated utero-ovarian ligaments. Because of the abnormal anatomy and the friability of the left ovary, performing oophoropexy was not technically feasible.

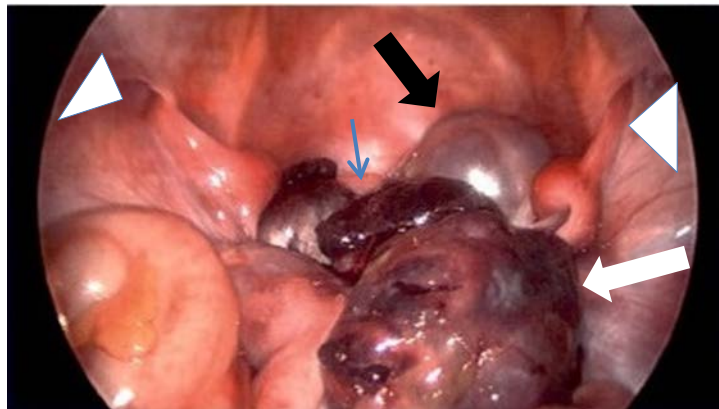


Figure 1: After laparoscopic exploration, we determined that the left adnexa (white arrowhead) was twisted 360 degrees. It also appeared dusky on initial entry. The right adnexa (black arrowhead) was normal-appearing and smaller in size compared to the left. Remnants of Müllerian structures (blue arrow) were noted, as well as each round ligament entering the anterior abdominal wall (triangles)

The patient had an unremarkable recovery with immediate resolution of her pain allowing discharge home the following morning. Subsequent office visits have confirmed normal ovarian size with no further symptoms of ovarian hyperstimulation syndrome. The patient and her husband are currently in the process of selecting a gestational carrier.

Summary and Conclusion

Given the incidence of Müllerian agenesis of 1 per 4,000-10,000 females, most general gynecologists may have limited contact with these rare anomalies in the course of their careers. Patients with Mayer-Rokitansky-Kuster-Hauser have a 46, XX karyotype and a normal hormonal profile. They typically present with primary amenorrhea in their teenage years and may be first diagnosed by a pediatrician or adolescent gynecologist. Most patients have normal height, secondary sexual characteristics, body hair and external genitalia. Patients undergo normal thelarche and pubarche with intact ovarian function. Typically, there is a rudimentary uterus with aplasia of the cervix and vagina and normal bilateral adnexa.⁴ Phenotype however may vary, and some patients may also suffer from renal, skeletal or cardiac abnormalities.¹

In general, the risk of ovarian torsion is thought to be increased in adolescent women with longer utero-ovarian ligaments and laxity in ovarian support leading to increased mobility of the ovary.⁵ It may therefore follow that having total absence of utero-ovarian ligaments and absence of the uterus

creating more free space in the pelvis in patients with Müllerian agenesis compared to those patients with these structures, could increase the risk of adnexal torsion.⁵⁻⁶ There have been case reports of ovarian torsion in patients with Mayer-Rokitansky-Kuster-Hauser due to the presence of uterine remnant leiomyomas⁷ and in adolescence.⁵ However, there are currently no other case reports of ovarian torsion in the setting of controlled ovarian hyperstimulation in this population (using search terms Müllerian agenesis, Mayer-Rokitansky-Kuster-Hauser syndrome, uterovaginal agenesis, ovarian torsion, and adnexal torsion).

The surgically induced absence of ovarian support that may occur after tubal sterilization or hysterectomy with bilateral salpingectomy could provide further information on the ligamentous support of the ovary preventing torsion. Currently, there is little research on this topic, however one study suggests that tubal sterilization increases the risk of ovarian torsion, while hysterectomy with ovarian conservation does not.⁸ Given the low prevalence of Mayer-Rokitansky-Kuster-Hauser syndrome, whether or not ovarian torsion is statistically more common in patients with this condition is unknown and further research is needed.

Another unique anatomical factor to consider during oocyte retrieval in a patient with Mayer-Rokitansky-Kuster-Hauser syndrome is whether the oocytes may be retrieved transvaginally or abdominally. A recent systematic review shows that transvaginal oocyte

retrieval is feasible in the majority of patients with this condition.¹ However, for the minority of patients with vaginal agenesis or ectopically located ovaries high in the abdomen, an abdominal ovum pickup technique has been described. Using an abdominal ultrasound probe and the traditional 17-gauge needle, oocytes may be collected by abdominal aspiration with one puncture site per ovary.⁹

Ovarian torsion can occur intermittently, which may explain the patient's initial discomfort and then worsening, severe pain. A transvaginal ultrasound and Doppler study demonstrated blood flow bilaterally to the ovaries early in the course of her presentation when her abdominal pain was less severe. Normal Doppler flow has been noted in up to 60% of adnexal torsion cases, so it is important to keep ovarian torsion in the differential diagnosis even with ultrasound documented Doppler flow. The most consistent ultrasonographic finding for ovarian torsion is increased size of the affected ovary compared to the contralateral side, which is a result of compression of the ovarian venous plexus limiting drainage of blood from the ovary.³ If on Doppler ultrasound a characteristic whirlpool sign of the twisted and coiled ovarian vessels is seen, this has high specificity.³

The ideal treatment for ovarian torsion is laparoscopy with untwisting of the adnexa; however, some surgeons also perform oophoropexy in an attempt to prevent recurrent torsion. Oophoropexy may be anatomically challenging or not technically feasible in women with Müllerian agenesis. There are currently no randomized prospective studies of oophoropexy done at the time of ovarian

torsion. Potential benefits include prevention of recurrence in the affected ovary as well as future torsion in the contralateral ovary. Techniques to perform oophoropexy include suturing the ovary to the pelvic sidewall, plication of the utero-ovarian ligament and suturing the ovary to the posterior wall of the uterus. Risks include potential compromise to the ovarian blood supply, risk of adhesions and anatomical distortion with possible fertility implications.¹⁰ We considered the possibility of oophoropexy for this patient, but we did not feel it was technically feasible intra-operatively secondary to ovarian friability and anatomical considerations. The only technique one could perform in a patient with Müllerian agenesis would be suturing the ovary to the pelvic sidewall. Our patient was instructed to avoid exercise for four weeks until her ovaries returned to their original size. She did not have recurrence of ovarian torsion within the following year.

Given the advances in assisted reproductive technology and improvement in access, it may be increasingly common for gynecologists to discuss fertility options with patients with Müllerian agenesis prior to referral to a reproductive endocrinologist. When undergoing ovarian stimulation, this population may be at increased risk of ovarian torsion. It is important to discuss this with patients, and it is critical to recognize and surgically manage suspected ovarian torsion to preserve ovarian function and fertility in these women.

References

1. Friedler S, Grin L, Liberti G, Saar-Ryss B, Rabinson Y, Meltzer S. The reproductive potential of patients with Mayer-Rokitansky-Küster-Hauser syndrome using gestational surrogacy: a systematic review. *Reprod Biomed Online*. 2016 Jan;32(1):54-61. <https://doi.org/10.1016/j.rbmo.2015.09.006> Epub 2015 Sep 25. PubMed PMID: 26626805.
2. Choussein S, Nasioudis D, Schizas D, Economopoulos KP. Mullerian dysgenesis: a critical review of the literature. *Arch Gynecol Obstet*. 2017 Jun;295(6):1369-1381. <https://doi.org/10.1007/s00404-017-4372-2> Epub 2017 Apr 22. PubMed PMID: 28434104.
3. Baron KT, Babagbemi KT, Arleo EK, Asrani AV, Troiano RN. Emergent complications of assisted reproduction: expecting the unexpected. *Radiographics*. 2013 Jan-Feb;33(1):229-44. <https://doi.org/10.1148/rg.331125011> PubMed PMID: 23322839.
4. Committee on Adolescent Health Care. Committee opinion: no. 562: müllerian agenesis: diagnosis, management, and treatment. *Obstet Gynecol*. 2013 May;121(5):1134-7. <https://doi.org/10.1097/01.AOG.0000429659.93470.ed> PubMed PMID:23635766.
5. Sullivan EM, Golden NH, Adams Hillard PJ. Ovarian torsion in a patient with müllerian agenesis: increased risk? *J Pediatr Adolesc Gynecol*. 2012 Dec;25(6):e125-8. <https://doi.org/10.1016/j.jpag.2012.08.001> Epub 2012 Oct 23. PubMed PMID: 23095528.
6. Kives SL, Bond SJ, Lara-Torre E. Müllerian agenesis and ovarian torsion. A case report and review of literature. *J Pediatr Surg*. 2005 Aug;40(8):1326-8. <https://doi.org/10.1016/j.jpedsurg.2005.05.022> PubMed PMID: 16080941.
7. Kundu K, Cohen AW, Goldberg J. Acute torsion of uterine remnant leiomyoma with Mayer-Rokitansky-Küster-Hauser syndrome. *Fertil Steril*. 2014 Aug;102(2):607-9. <https://doi.org/10.1016/j.fertnstert.2014.04.034> Epub 2014 May 17. PubMed PMID: 24842677.
8. Asfour V, Varma R, Menon P. Clinical risk factors for ovarian torsion. *J Obstet Gynaecol*. 2015;35(7):721-5. <https://doi.org/10.3109/01443615.2015.1004524> Epub 2015 Jul 27. PubMed PMID: 26212687.
9. Raziel A, Vaknin Z, Schachter M, Strassburger D, Herman A, Ron-El R, Friedler S. Ultrasonographic-guided percutaneous transabdominal puncture for oocyte retrieval in a rare patient with Rokitansky syndrome in an in vitro fertilization surrogacy program. *Fertil Steril*. 2006 Dec;86(6):1760-3. Epub 2006 Oct 30. <https://doi.org/10.1016/j.fertnstert.2006.05.039> PubMed PMID: 17074340.
10. Fuchs N, Smorgick N, Tovbin Y, Ben Ami I, Maymon R, Halperin R, Pansky M. Oophoropexy to prevent adnexal torsion: how, when, and for whom? *J Minim Invasive Gynecol*. 2010 Mar-Apr;17(2):205-8. <https://doi.org/10.1016/j.jmig.2009.12.011> PubMed PMID: 20226409.