

A case of uterine gangrene after termination of second trimester pregnancy complicated by chorioamnionitis

Mohammed N. Salem,¹ Ibrahim M. A. Hassanin,¹ Ahmed M. Abbas²

Keywords: Uterine gangrene, chorioamnionitis, second trimester pregnancy

Abstract

Uterine gangrene is a rare event during pregnancy. Here, we report the case of a 22-year-old patient pregnant in her second trimester presenting with premature rupture of membranes and a low-lying placenta. Hysterotomy was done to evacuate the pregnancy. The procedure was complicated by hemorrhage so bilateral uterine arteries and the left internal iliac artery were ligated to control the bleeding. She continued to run a fever in spite of antibiotics and on the 11th postoperative day, the patient developed signs of septicemia. Abdominal re-exploration was done revealing a gangrenous uterus with signs of peritonitis. Subtotal hysterectomy was done. The patient was discharged from the hospital in good health on the 10th post repeat laparotomy day.

¹Department of Obstetrics and Gynecology, Sohag University, Sohag, Egypt

²Department of Obstetrics and Gynecology, Assiut University, Assiut, Egypt

Introduction

Uterine gangrene is an extremely rare occurrence, as the uterus has a double blood supply.¹ Septic endometritis is one

of the major risk factors for uterine gangrene especially if there is co-infection with clostridia organism. Second trimester premature rupture of membranes (PPROM) occurs in less than 1% of pregnancies.² Subsequent chorioamnionitis can lead to severe complications, like septicemia and pelvic thrombophlebitis if the patient is left neglected.³ Pelvic devascularization is one of the conservative methods for management of intraoperative hemorrhage due to low-lying or morbidly adherent placenta.⁴

In cases of abnormal placentation and chorioamnionitis with evidence of septicemia, all these factors predispose to occlusion of the uterine blood supply (either uterine or ovarian vessels) resulting in marked uterine ischemia. Uterine gangrene could be the end result of neglected ischemia.

Please cite this paper as: Salem MN, Hassanin IMA, Abbas AM. A case of uterine gangrene after termination of second trimester pregnancy complicated by chorioamnionitis. Proc Obstet Gynecol. 2018;8(2): Article 5 [5 p.]. Available from: <http://ir.uiowa.edu/pog/> Free full text article.

Corresponding author: Ahmed M. Abbas, MD, Department of Obstetrics and Gynecology, Assiut University, Assiut, Egypt; Woman's Health Hospital, 71511, Assiut, Egypt, Cellular: +2010033851833; Tel: +20882414616; email: bmr90@hotmail.com

Financial Disclosure: The authors report no conflict of interest.

Copyright: © 2018 Salem et al. This is an open-access article distributed under the terms of the Creative Commons Attribution License, which permits unrestricted use, distribution, and reproduction in any medium, provided the original author and source are credited.

Case presentation

History:

A 22-year-old woman, G2 P1+0, with one living male child, pregnant at her 24th week of gestation presented with fever, PPROM and mild vaginal bleeding.

Investigations:

Complete blood picture revealed

Leukocytosis (WBCs=18000/mm³) and mild anemia (Hemoglobin=10 gm/dL). Ultrasonographic evaluation revealed a single living fetus with average biometry of 24 weeks, drained amniotic fluid and low implanted placenta below the presenting part on the anterior uterine wall reaching the site of previous scar. She had a history of cesarean section (CS) in her first pregnancy due to intra-partum fetal distress 2 years ago.

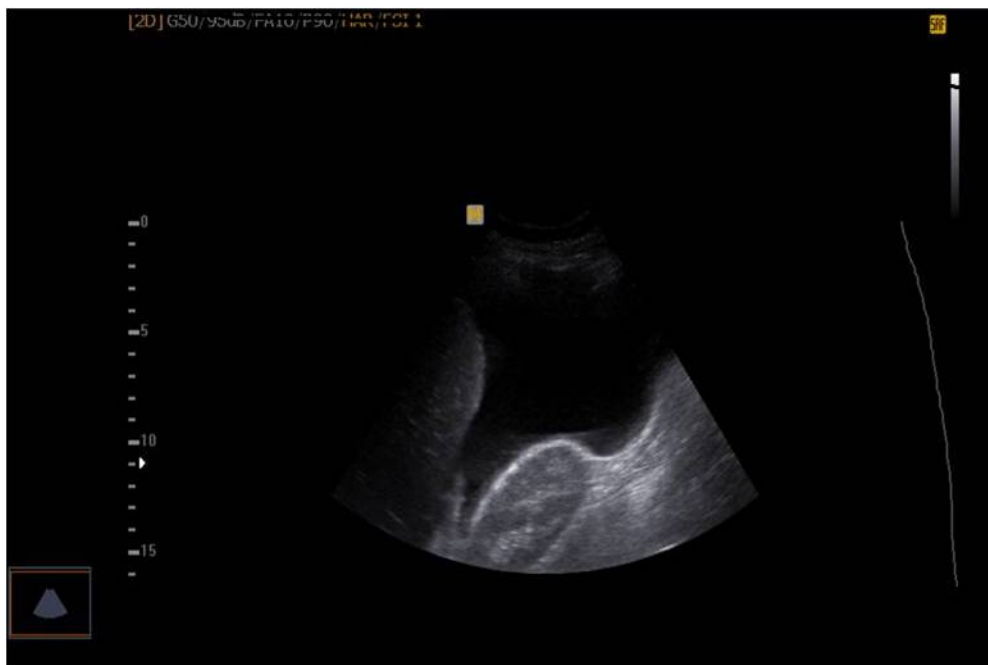


Figure 1: Abdominal ultrasonography revealed marked intraperitoneal collection.

Management:

Based on the previous data, delivery was planned through hysterotomy. Conservative treatment was not an option due to the high risk of septicemia with the signs of chorioamnionitis and the persistence of vaginal bleeding therefore this option was not discussed with the patient or her relatives.

Complete extraction of the placenta was difficult with bleeding from the placental bed; however, all efforts of conservative management were performed to preserve the uterus due to the patient's low parity. Intraoperative hemorrhage was successfully controlled with multiple square sutures in the placental bed followed by ligation of bilateral uterine arteries and the left internal iliac artery.

The abdomen was closed with an intra-abdominal drain left in the pelvis. The patient received 3 units of packed RBCs and was transferred to the postoperative intensive care unit (ICU). The fetal birth weight was 750 grams with Apgar score 3/10 at 1 minute and he was transferred to the neonatal ICU.

Postoperative course was complicated by persistent fevers in spite of the strong antibiotics given (Imipenem and Cilastatin, Tinam[®], Merck) 500 mg IV

infusion/8 hours, (Metronidazole, Flagyl[®], Sanofi-Aventis) 500 mg IV and antipyretic (Paracetamol, Perfalgan[®], Bristol-Myers) for 10 days. Over these 10 days, the consciousness level of the patient deteriorated. On the 11th postoperative day, the patient developed pneumonia and hemoptysis with expectoration of pus. Significant abdominal distension occurred and abdominal ultrasonography revealed marked intraperitoneal fluid collection (Figure 1).

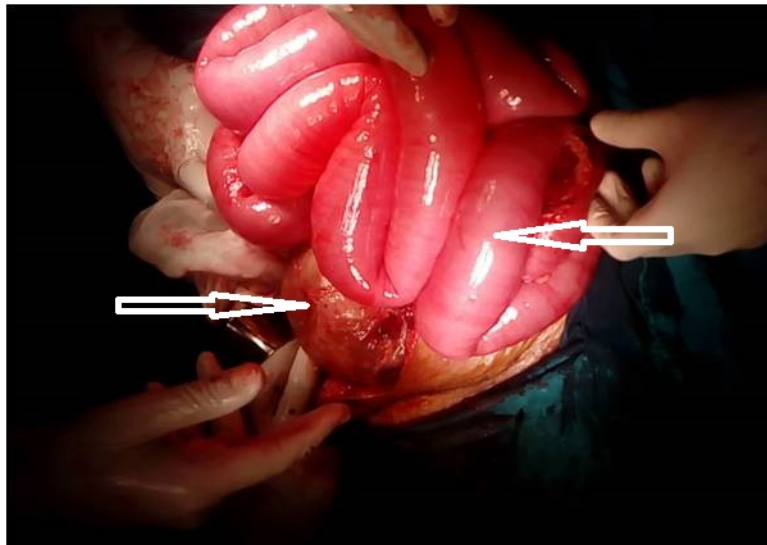


Figure 2: Dilated intestinal loops (Right arrow) and lax distended uterus (Left arrow) at abdominal exploration.

Abdominal re-exploration was carried out through a midline incision and revealed foul-offensive bloody fluid filling the peritoneal cavity with dilated intestinal loops (Figure 2). The uterus was lax and distended with pus that emerged from the tubal fimbria on handling. Incision of the uterine wall revealed that the myometrium was black in color (gangrenous) (Figure 3), the

cavity was filled with offensive pus; the decidua was black in color and covered with a pyogenic membrane.

Subtotal hysterectomy with preservation of both ovaries was performed. Intraoperative findings included thrombosis and occlusion of all major vasculature supplying the uterus including both uterine and ovarian

vessels. Repeated peritoneal lavage was carried-out. An intra-abdominal

drain was inserted followed by closure of the abdomen.

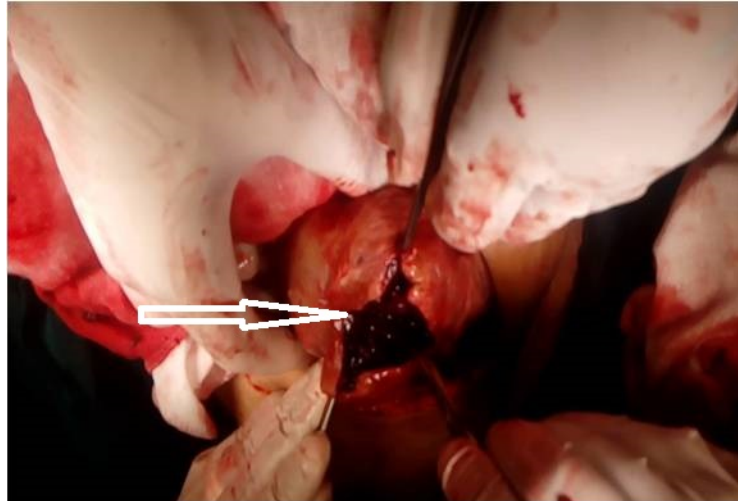


Figure 3: Distended uterus with anterior uterine wall gangrene; black area (Left arrow)

The patient was readmitted to the ICU for postoperative management. She was kept on a mechanical ventilator for 3 days and received 7 units of cross matched fresh whole blood. On the 4th day post repeat laparotomy, dramatic improvement had occurred and the patient was weaned from the mechanical ventilator. She was discharged from the ICU on the 7th day post repeat laparotomy to the routine care department. Finally, the patient was discharged from the hospital on the 10th day post repeat laparotomy in a healthy state.

Conclusion

In conclusion, vascular ligation of the major pelvic vessels to stop any intraoperative hemorrhage in cases of morbidly adherent placenta or uterine atony can end with uterine ischemia and progress to gangrene if associated with

intrauterine infections. Pelvic thrombophlebitis can hinder the reperfusion of the pelvic organs. Therefore, obstetricians should pay attention to this consequence in cases with placenta previa/accreta complicated by PPRM and chorioamnionitis.

References

1. Sokol E. Clinical anatomy of the uterus, fallopian tubes and ovaries. Glob. Libr. Women's Med. 2011. DOI 10.3843/GLOWM.10001
2. Dinsmoor MJ, Bachman R, Haney EI, Goldstein M, Mackendrick W. Outcomes after expectant management of extremely preterm premature rupture of the membranes. Am J Obstet Gynecol. 2004 Jan;190(1):183-7. [https://doi.org/10.1016/S0002-9378\(03\)00926-8](https://doi.org/10.1016/S0002-9378(03)00926-8) PubMed PMID: 14749657.

3. Tita AT, Andrews WW. Diagnosis and management of clinical chorioamnionitis. Clin Perinatol. 2010 Jun;37(2):339-54.
<https://doi.org/10.1016/j.clp.2010.02.003>
PubMed PMID: 20569811; PubMed Central PMCID: PMC3008318.

4. Johnston TA, Paterson-Brown S. Placenta praevia, placenta praevia accreta and vasa previa: diagnosis and management. Royal College of Obstetricians and Gynaecologists (RCOG) Green-Top Guideline No.27. London, UK: RCOG, 2011(updated 2014):1-26.
<https://www.guidelinecentral.com/summaries/placenta-praevia-placenta-praevia-accreta-and-vasa-praevia-diagnosis-and-management/>