Consequences of unsafe abortion in India—a case report

Sanjoy Kumar Bhattacharyya, MS,[1] Shyama Prasad Saha, MD,[1] Sohini Bhattacharya, MD,[1] Ranjan Pal, MD[1]

Key Words: maternal mortality, India, unsafe abortion

Abstract

Unsafe abortion represents a preventable yet major cause for maternal mortality in India. A majority of these abortions are performed confidentially. Complications occur in a large portion of these cases and ultimately require tertiary care. However, patients and their relatives often fail to disclose the abortion despite the critical state of the patients. This scenario creates considerable confusion for diagnosis and treatment and can lead to further complications. This case report of complications associated with an unsafe abortion in India highlights the need for clinicians to consider the possibility of an undisclosed abortion when treating any morbid woman of reproductive age.

[1] *North Bengal Medical College, Darjeeling, West Bengal, India*

Introduction

Unsafe abortion is defined as an induced abortion process either conducted by unskilled personnel or performed in a non-accredited facility.[1] In third World countries, unsafe abortions are attributed to maternal mortality and morbidity.[2] In India, the majority of these events remain concealed initially, thereby further complicating the scenario.[3] The purpose of this case report is to educate and caution clinicians to consider the possibility of clandestine abortion while dealing with any morbid woman of reproductive age.

Case Report

Mrs. A.M., 41 years old, mother of four children, was admitted with fever, pain, and abdominal distension persisting for the last five days. The patient had a history of amenorrhea of an unspecified duration. On examination she was well-oriented, with a mild fever, moderate pallor, tachycardia, and moderate distension of the abdomen with sluggish peristaltic sounds. Vaginal examination revealed a bulky, soft uterus of 8-10 weeks size. Peritoneal tap was inconclusive. Urine tested negative for pregnancy. Despite repeated inquiry, the patient denied any recent history of interference of pregnancy. Trans abdominal sonography revealed distended bowel

Please cite this paper as: Bhattacharyya SK, Saha SP, Bhattacharya S, Pal R. Consequences of unsafe abortion in India—a case report. Proc Obstet Gynecol. 2011 November;2(2):Article 12 [4 p.]. Available from: http://ir.uiowa.edu/pog/. Free full text article.

Corresponding author: *Sanjoy Kumar Bhattacharyya,* North Bengal Medical College, Darjeeling, West Bengal, India, *sanjay.krbhattacharyya@gmail.com*

loops and a bulky, empty uterus along with fluid collection in the pouch of Douglas (P.O.D.). She was initially managed conservatively with antibiotics ceftriaxone one gram twice a day and metronidazole 200 mg and gentamycin 80 mg three times a day. Unfortunately her condition deteriorated and laparotomy was performed on the third day after admission. It revealed a pyoperitoneum and a uterine perforation with a mutilated, putrefied fetus of approximate 24 weeks gestational age adherent in the P.O.D. (Picture). Drainage of the purulent material and removal of the fetus and fetal parts from the peritoneal cavity was performed. Hysterectomy was performed as the uterus was lacerated to such an extent that it could not be repaired. No other visceral injury was noticed. The woman recovered gradually and was discharged on the tenth postoperative day.

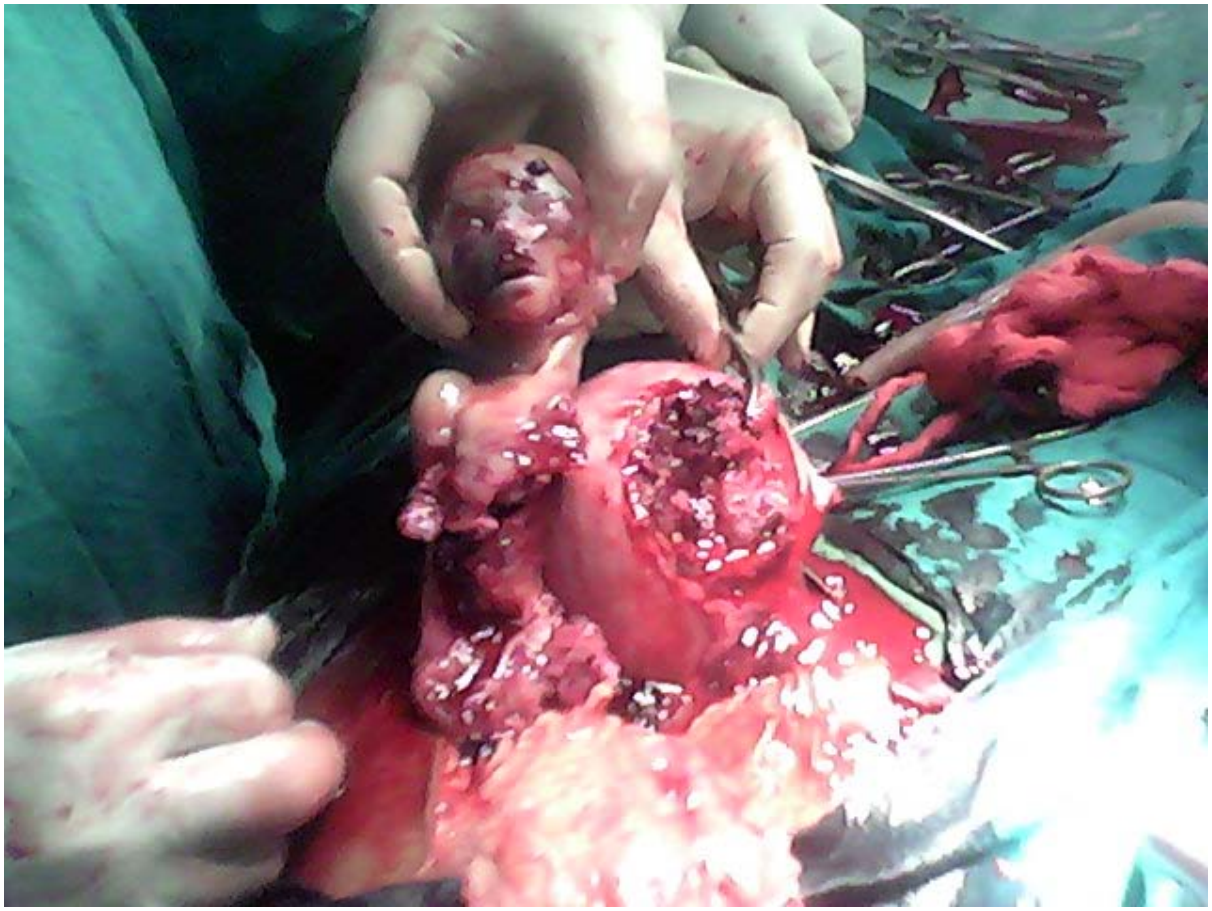

Laparotomy finding: showing perforated uterus and mutilated putrefied fetus taken out from the Pouch of Douglas.

Discussion

According to World Health Organization, in every 8 minutes a woman in one of the developing nations will die of complications arising from unsafe abortion, making it one of the leading causes of maternal mortality (13%).[1] Study reveals that out of 42 million abortions performed world-wide, nearly 20 million are unsafe.[4] Under the Revised Medical Termination of Pregnancy Act (MTP act) in India, both the caregiver and the patient are held liable for unsafe abortion.[3] Apart from social stigma, this may be one of the causes of deliberate suppression of abortion-related facts, as viewed in this case. Features of peritonitis, history of amenorrhea and unexplainable bulky, soft uterus compelled us to consider the possibility of unsafe abortion in our diagnosis and proceed accordingly.

It is important to note that urine tests for pregnancy may appear negative if the abortion was not recently performed. Thus, a negative pregnancy test cannot exclude the possibility of complications associated with unsafe abortion. Accordingly, similar case reports related to complications following unsafe abortion also reported a negative urine tests for pregnancy.[5]

Uterine perforation, bleeding, injury to bladder and bowel, sepsis, shock and death are immediate complications of unsafe abortion.[4] In this case, unskilled instrumentation likely perforated the gravid uterus near its cornu, through which the mutilated fetus escaped intraperitoneally. However, the patient's relatively stable condition and absence of haemoperitoneum on examination initially misled us and could not be explained with such an extensive uterine injury. The absence of other visceral injury favored the prognosis of this woman. Unsafe abortion has also been associated with long-term adverse conditions, including vesicovaginal fistula, rectovaginal fistula, bowel resection, chronic pelvic inflammatory disease (PID) and infertility.[4]

Although there is a declining global trend in the incidence of abortion, surprisingly, unsafe abortion rates are gradually escalating, especially in the developing World.[6] Despite liberalization of MTP acts, decentralization of MTP units, and generous provision of family planning devices, this trend continues. However, the statistics of unsafe abortions likely underestimate the number of events. For example, desperate attempts to conceal these unsafe abortions, as in this case, prevent to measure the true estimates. A second major issue associated with concealed abortions is the inability of caregivers to provide optimal patient care due to a lack of information. Thus, clinicians must consider unsafe abortion in these and similar circumstances rather than to rely on the patient, fearful of the consequences of full disclosure.

Conclusion

The incidence of unsafe abortion is rising globally. Most remain

undisclosed and thus prevent to measure the accurate estimates of the incidence. Caregivers are often faced with difficulties in dealing with complicated abortion processes, as even critically ill patients remain surprisingly silent about previous and recent pregnancy terminations. In these extreme cases, the patients apparently prefer death to disclosure. Thus, to avert these maternal deaths, the caregiver should consider the possibility of an undisclosed unsafe abortion when treating any woman of reproductive age with unexplained morbidity.

LIST OF ABBREVIATIONS

M.T.P. --- Medical Termination of Pregnancy
P.O.D. --- Pouch of Douglas
P.I.D.—Pelvic inflammatory disease

REFERENCES

1. World Health Organization. Unsafe abortion: global and regional estimates of the incidence of unsafe abortion and associated mortality in 2003. 5th ed. Geneva: World Health Organization; 2007. 56 p.

2. Khan KS, Wojdyla D, Say L, Gülmezoglu AM, Van Look PF. WHO analysis of causes of maternal death: a systematic review. Lancet. 2006 Apr 1;367(9516):1066-74.

3. Santhya KG, Verma S. Induced abortion: the current scenario in India. Regional Health Forum. 2004;8(2):1-14.

4. Haddad LB, Nour NM. Unsafe abortion: unnecessary maternal mortality. Rev Obstet Gynecol. 2009 Spring;2(2):122-6.

5. Puri M, Goyal U, Jain S, Pasrija S. A rare case of vesicovaginal fistula following illegal abortion. Indian J Med Sci. 2005 Jan;59(1):30-1.

6. Sedgh G, Henshaw S, Singh S, Ahman E, Shah IH. Induced abortion: estimated rates and trends worldwide. Lancet. 2007 Oct 13;370(9595):1338-45.