

## **A late-onset hematoma developed after sexual intercourse following sacrospinous hysteropexy and mid-urethral sling surgery: case report**

Ozan Doğan,<sup>1</sup> Çiğdem Pulatoğlu,<sup>2</sup> Alper Başbuğ,<sup>3</sup> Deniz Yüceer<sup>4</sup>

**Keywords:** Sacrospinous ligament fixation, bleeding, pelvic hematoma

### **Abstract**

*Introduction:* Sacrospinous hysteropexy is a minimally invasive surgical procedure option for apical prolapse repair. Despite a significant number of postoperative hemorrhage and hematoma cases reported in the literature, life-threatening hemorrhage as a complication after sacrospinous hysteropexy is rare. In this case, in addition to sacrospinous hysteropexy, midurethral sling surgery was performed via the needleless technique for stress urinary incontinence. The case presented here is of a hematoma that developed following sexual intercourse on the 10th postoperative day after sacrospinous hysteropexy and its successful management and treatment without re-operation. A review of the literature did not reveal any cases similar to the present one.

*Method:* Both sacrospinous hysteropexy using the Surelift® Contasure Prolapse System and midurethral sling surgeries were performed without any intraoperative complications.

*Case:* A 40-year-old, female patient who had undergone both sacrospinous hysteropexy and midurethral sling surgery presented with pain following sexual intercourse on the 10<sup>th</sup> postoperative day. A hematoma of 4 cm was palpated at vaginal examination on the right

*posterolateral site and confirmed with computed tomography (CT) and magnetic resonance imaging (MRI). A vaginal tamponade was put in place and removed after 2 days follow-up in the hospital. After two weeks, contrast MRI revealed a hematoma smaller in size and after one month the hematoma was not observed.*

*Discussion:* Vascularity of the sacrospinous ligament (SSL) space includes an abundance of collateral blood vessels and significant anatomical variations can result from anastomosis. Finding and repairing injured vessels during SSL and pararectal area surgeries transvaginally or via laparotomy is difficult even for the experienced surgeon. Although sacrospinous hysteropexy is a minimally invasive transvaginal procedure, adverse effects may result due to the physical trauma of sexual intercourse so the patient should be warned to avoid sexual intercourse during the postoperative recovery period. If concurrent procedures have been performed along with sacrospinous hysteropexy, finding the source of the complication is essential for management and treatment.

*Conclusion:* Knowledge of treatment options and pelvic vascular anatomy is fundamental for the diagnosis and management of complications. Although the literature is lacking in relevant data

Please cite this paper as: Doğan O, Pulatoğlu Ç, Başbuğ A, Yüceer D. A late-onset hematoma developed after sexual intercourse following sacrospinous hysteropexy and mid-urethral sling surgery: case report. *Proc Obstet Gynecol.* 2017;7(2): Article 5 [ 8 p.]. Available from: <http://ir.uiowa.edu/pog/>. Free full text article.

**Corresponding author:** Çiğdem Pulatoğlu, MD, Department of Obstetrics and Gynecology Bayburt Government Hospital, Bayburt, Turkey, email: [ciqdepulatoğlu@gmail.com](mailto:ciqdepulatoğlu@gmail.com)

**Financial Disclosure:** The authors report no conflict of interest.

Copyright: © 2017 Doğan et al. This is an open-access article distributed under the terms of the Creative Commons Attribution License, which permits unrestricted use, distribution, and reproduction in any medium, provided the original author and source are credited.

and case studies, the example of this case indicates that having sexual intercourse can result in postoperative development of hematoma in the SSL area, and that the patient should be warned to avoid sexual intercourse during the 6-week postoperative period. Vaginal packing should be the first treatment approach for management of intraoperative and postoperative hematoma and hemorrhage.

<sup>1</sup>Department of Obstetrics and Gynecology, Duzce Ataturk Government Hospital, Duzce, Turkey

<sup>2</sup>Department of Obstetrics and Gynecology, Bayburt Government Hospital, Bayburt, Turkey

<sup>3</sup>Department of Obstetrics and Gynecology, Duzce University Hospital, Duzce, Turkey

<sup>4</sup>Department of Radiology, Duzce Ataturk Government Hospital, Duzce, Turkey

## **Introduction**

Sacrospinous is a minimally invasive surgery performed for apical prolapse repair and can result in complications such as bleeding, hematoma, pain, need for removal, prolapse recurrence intraoperatively or postoperatively.<sup>1,2</sup> Despite a significant number of postoperative hemorrhage and hematoma cases reported in the literature, life-threatening hemorrhage as a complication during sacrospinous hysteropexy is rare. In this case, the hematoma developed on the 10<sup>th</sup> postoperative day following sexual intercourse. A review of the literature did not reveal any cases similar to the present one. In addition to the sacrospinous hysteropexy, midurethral sling surgery was performed for stress urinary incontinence. The case presented here is of a hematoma developed following sexual intercourse on the 10<sup>th</sup> sacrospinous hysteropexy postoperative day and its successful management and treatment without re-operation.

## **Case**

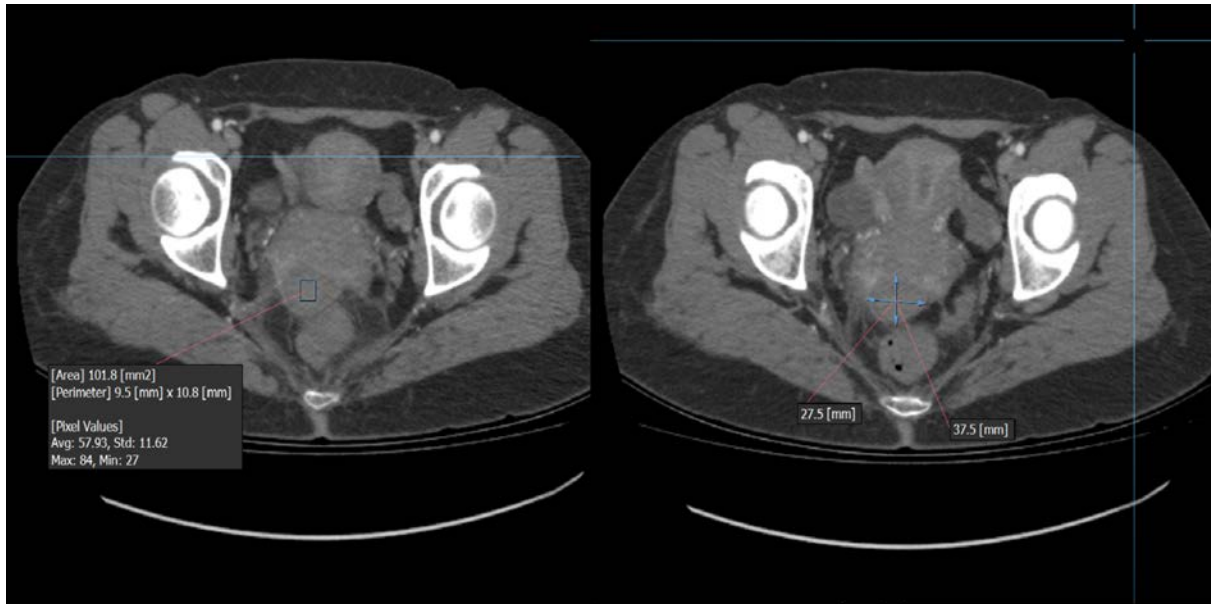
A 40-year-old, gravida 2 parity 2 female patient presented with symptomatic grade 3 anterior and apical pelvic organ prolapse and stress urinary incontinence. The patient desired surgery with uterus conservation. Both sacrospinous hysteropexy using the Surelift® Contasure Prolapse System and midurethral sling surgery via needleless technique were planned.

Preoperation hemoglobin (Hb) concentration was 12.1 g/dl. Intraoperatively, a 2-cm transverse incision was performed on the posterior of the uterus. With sharp and blunt dissection, the right ischial spine and sacrospinous ligament were palpated between the peritoneum and the vaginal wall. A tissue anchor was fixed to the area using the Surelift® Contasure Prolapse System. Without any intraoperative complication, sutures were tied at the anchors after running through the posterior wall of the uterus. Afterwards, for the mid-urethral sling operation, a 1-cm incision was made below the external urethra and the bilateral paraurethral spaces were sharply and bluntly dissected to the pubic ramus. Both arms of the mesh were fixed to the fascia of the obturatoria interna without any complication.

At the end of the operation, a vaginal tamponade was placed at the right SSL area. On postoperative day 1, the patient was well, her vitals were stable and there was no remarkable decrease in the blood count (Hb:11.7g/dl). Upon vaginal examination, the incision line was clear with no evident bleeding or signs of hematoma, and the patient was

discharged. On the 10th postoperative day, the patient registered at the emergency room complaining of sharp, acute pain following sexual intercourse, with the pain increasing upon defecation. Following vaginal and rectal examination, a hematoma of about 4 cm was palpated at the 6-9 o'clock area, deviating to the left of the rectum.

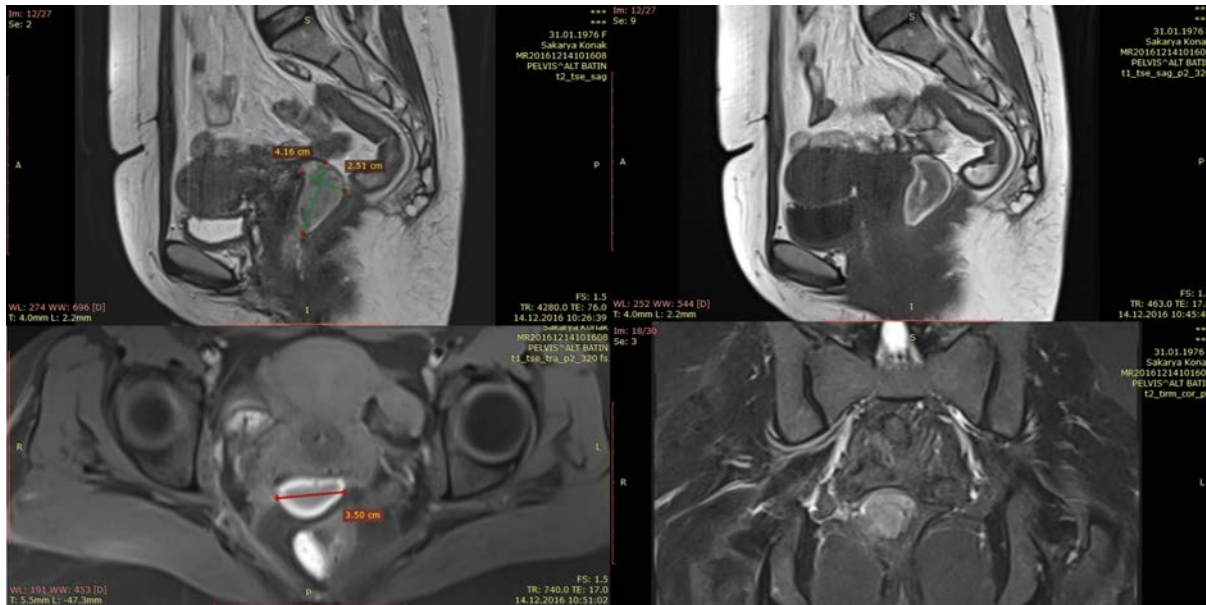
Contrast-enhanced arterial phase CT revealed a 25 x 35 x 41 mm subacute hematoma originating from the margin of the right posterolateral cervix, filling the right fornix of the vagina and extending to the recto-uterine pouch (Figure 1). The subacute hematoma was confirmed by MR imaging (Figure 2).



**Figure 1.** In the contrast-enhanced arterial phase CT, the subcutaneous hematoma is observed starting from the right posterolateral vicinity of the uterine cervix, filling the right fornix of the vagina and extending to the recto-uterine pouch.

The patient was hospitalized and a vaginal tamponade was put in place. A Foley catheter was also placed for observation. Total blood count was taken and vital signs were observed. The Hb concentration was 10.1 g/dl. The patient remained hemodynamically stable and afebrile and signs or symptoms of infection were absent. No significant changes were observed in

the 2-days follow-up. The vaginal packing was removed, the hematoma dimensions remained stable in the control ultrasound imaging and the patient was discharged after 2 days in the hospital. A laxative diet and medication were recommended to prevent constipation. As there were no symptoms or signs of infection, antibiotics were not administered.



**Figure 2. MR images of the subacute hematoma**

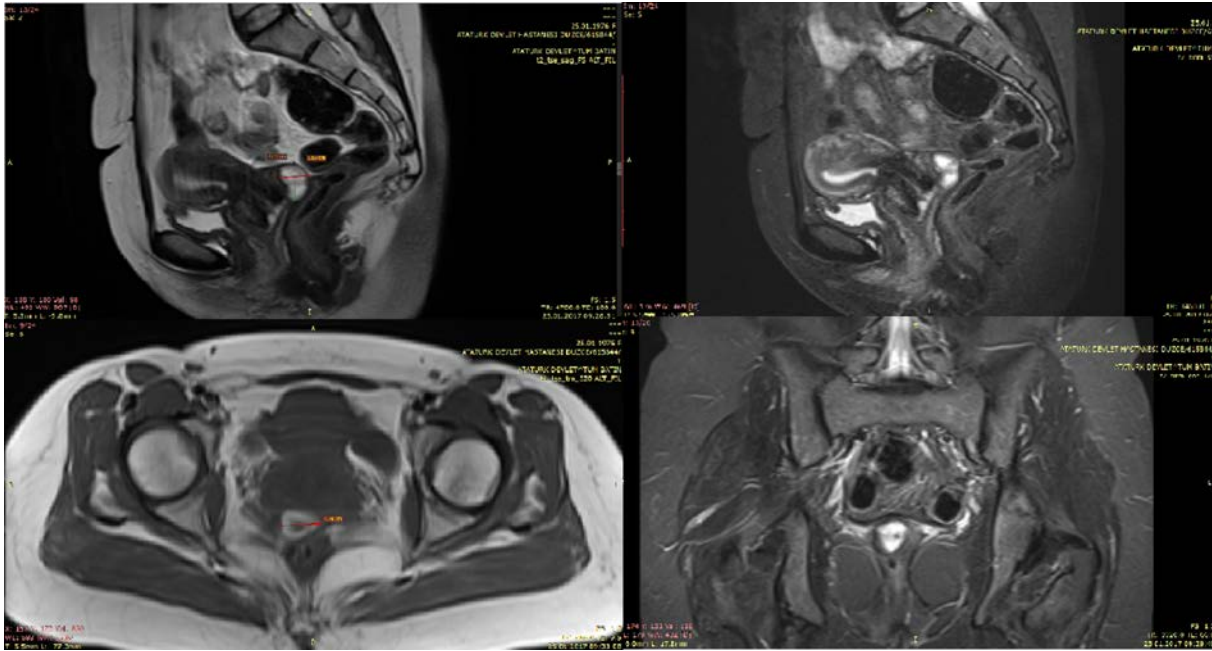
After two weeks, contrast MRI revealed a subacute-chronic hematoma with dimensions of 15x22x25 mm that shrunk in size according to previous evaluations (Figure 3). The patient was feeling better. After one month the hematoma was not observed upon examination and ultrasound imaging and the patient's complaints had completely resolved.

### **Discussion**

Surgeries in the SSL region require experienced surgeons with critical anatomic knowledge of veins that are susceptible to injury. In this case, both surgeries were performed by an experienced and specialized surgeon. Life-threatening bleeding after sacrospinous hysteropexy is rare. Notable cases of postoperative bleeding and hematoma managed with different treatment approaches can be found in the literature. Abdel-Fattah et al.<sup>3</sup> favored vaginal surgical exploration, evacuation of the infralevator hematoma

and suture of the injured vessel in a case of postoperative internal pudendal arterial bleeding. Araco et al.<sup>4</sup> chose to perform CT angiography embolization for postoperative bleeding from a branch of the hypogastric artery. David-Montefiore et al.<sup>5</sup> conducted laparotomy, drainage of the hematoma and injured vessel repair for a postoperative presacral and pararectal vessel injury. Muffly et al.<sup>6</sup> performed CT angiography embolization resulting from a postoperative inferior vesical artery injury. In this case the hematoma was managed minimally invasively and re-operation was avoided similar to other cases reported in the literature.<sup>7</sup> The complications in the literature were seen intraoperatively or 48 hours postoperatively. Moreover, there are no prospective studies that have specifically evaluated the presence of hematoma following sacrospinous hysteropexy. Late-onset subacute hematoma is a rare complication of

sacrospinous hysteropexy.



**Figure 3. MR images after 2 weeks. A-Sagittal plan T2 B- Sagittal plan oil-printed T2 C-Axial T1 D-Coronal plan T2 images.**

The present case is unique in that the hematoma developed following sexual intercourse on the 10<sup>th</sup> postoperative day.

A cadaveric study has shown an abundance of important collateral anatomic variations in the vascularity of the SSL region. Vessels susceptible to injury include the superior gluteal, inferior gluteal, internal pudendal, vertebral, middle sacral, lateral sacral and circumflex femoral veins.<sup>8</sup> Among these, the inferior gluteal artery and coccygeal rami are the most at risk to injury.<sup>8,9</sup> According to another study, venous injuries were found to occur in the hypogastric and the pudendal venous plexus.<sup>10,11</sup> In order to ensure that the patient is hemodynamically stable, the first application after blood

transfusion and vasopressors is the placement of a vaginal tamponade directly onto the SSL area. This will provide control for most of the venous bleeding.<sup>1</sup> In the present case, when the hematoma was detected, a vaginal tamponade was applied with pressure onto the SSL area and remained in place for 48 h. Monitoring of vital signs and urinary output, repeated blood counts every 4-6 h and white blood count checks were carried out. No remarkable signs or changes were detected within the parameters, and the stable dimensions of the hematoma demonstrated that the close follow-up and vaginal tamponade treatment had succeeded.

Although sacrospinous hysteropexy is a minimally invasive transvaginal

technique, physical trauma such as sexual intercourse may result in negative postoperative consequences in the region of the surgery. In this case, the hematoma could be a late presentation that was present immediately post-operatively, but it seemed to appear on the 10<sup>th</sup> day postoperatively, following sexual intercourse. Accordingly, patients should be cautioned to avoid sexual intercourse after sacrospinous hysteropexy surgery.

When concurrent procedures have been performed along with sacrospinous hysteropexy, the source of the complication must be determined in order to ensure proper management and treatment. In the present case, in addition to sacrospinous hysteropexy, midurethral sling surgery had been performed on the patient due to stress urinary incontinence. Physical examination, pelvic MRI and CT angiography revealed that the hematoma had developed only in the SSL region, thus indicating that the midurethral surgery had been performed successfully without complications.

Finding and repairing veins injured during SSL surgery performed either transvaginally or via laparotomy is very difficult, even for the most experienced surgeon, and the development of a hematoma makes the situation even more challenging. Hemorrhaging uncontrolled by tamponade treatment as well as dramatically enlarged arterial bleeding can be controlled safely with the embolization technique, which is a minimally invasive treatment choice.<sup>2</sup> Azais et al.<sup>12</sup> noted that hypogastric artery ligation was not the first choice of treatment because of the existence of

multiple anatomical variations and that anastomosis could also contribute to a failed procedure. In the present case there were no abnormal deviations requiring further evaluation or treatment and there were no additional complications.

## **Conclusion**

Knowledge of treatment options and pelvic vascular anatomy is essential for the diagnosis and management of complications. Although the literature is lacking in relevant data and similar case studies, the experience of the present case indicates that having sexual intercourse can cause development of a postoperative hematoma in the region of the SSL. Thus, the patient should be cautioned to avoid sexual intercourse for six weeks postoperatively. Vaginal packing should be the first treatment approach for management of intraoperative and postoperative hematoma and hemorrhage. According to the severity of the bleeding, pelvic vessel embolization can also provide an effective minimally invasive alternative to surgical re-exploration. If concurrent procedures have been performed along with the sacrospinous hysteropexy, the patient should be examined carefully and appropriate imaging studies should be used to clarify problems associated with the current complications. Consequently, the source of the complication should be determined with the aim of carrying out correct and appropriate management.

## References

1. Pahwa AK, Arya LA, Andy UU. Management of arterial and venous hemorrhage during sacrospinous ligament fixation: cases and review of the literature. *Int Urogynecol J*. 2016 Mar;27(3):387-91. <https://doi.org/10.1007/s00192-015-2818-2> PubMed PMID: 26282092.
2. Jain A, Sheorain VS, Ahlawat K, Ahlawat R. Vascular complication after sacrospinous ligament fixation with uterine preservation. *Int Urogynecol J*. 2017 Mar;28(3):489-491. <https://doi.org/10.1007/s00192-016-3121-6> PubMed PMID: 27539567.
3. Abdel-Fattah M, Ramsay I; West of Scotland Study Group. Retrospective multicentre study of the new minimally invasive mesh repair devices for pelvic organ prolapse. *BJOG*. 2008 Jan;115(1):22-30. <https://doi.org/10.1111/j.1471-0528.2007.01558.x> PubMed PMID: 18053100.
4. Araco F, Gravante G, Konda D, Fabiano S, Simonetti G, Piccione E. Selective embolization of the superior vesical artery for the treatment of a severe retroperitoneal pelvic haemorrhage following Endo-Stitch sacrospinous colpopexy. *Int Urogynecol J Pelvic Floor Dysfunct*. 2008 Jun;19(6):873-5. <https://doi.org/10.1007/s00192-007-0524-4> PubMed PMID: 18157494.
5. David-Montefiore E, Garbin O, Hummel M, Nisand I. Sacro-spinous ligament fixation peri-operative complications in 195 cases: visual approach versus digital approach of the sacro-spinous ligament. *Eur J Obstet Gynecol Reprod Biol*. 2004 Sep 10;116(1):71-8. <https://doi.org/10.1016/j.ejogrb.2003.12.020> PubMed PMID: 15294372.
6. Muffly TM, Paraiso MF, Gill AS, Barber MD, Rainey MC, Walters MD. Interventional radiologic treatment of pelvic hemorrhage after placement of mesh for reconstructive pelvic surgery. *Obstet Gynecol*. 2012 Feb;119(2 Pt 2):459-62. <https://doi.org/10.1097/AOG.0b013e31822ad840> PubMed PMID: 22270438.
7. Walters MD, Tulikangas PK, LaSala C, Muir TW. Vascular injury during tension-free vaginal tape procedure for stress urinary incontinence. *Obstet Gynecol*. 2001 Nov;98(5 Pt 2):957-9. <https://doi.org/10.1097/00006250-200111001-00028> PubMed PMID: 11704220.
8. Barksdale PA, Elkins TE, Sanders CK, Jaramillo FE, Gasser RF. An anatomic approach to pelvic hemorrhage during sacrospinous ligament fixation of the vaginal vault. *Obstet Gynecol*. 1998 May;91(5 Pt 1):715-8. <https://doi.org/10.1097/00006250-199805000-00014> PubMed PMID: 9572217.
9. Thompson JR, Gibb JS, Genadry R, Burrows L, Lambrou N, Buller JL. Anatomy of pelvic arteries adjacent to the sacrospinous ligament: importance of the coccygeal branch of the inferior gluteal artery. *Obstet Gynecol*. 1999 Dec;94(6):973-7. <https://doi.org/10.1097/00006250-199912000-00013> PubMed PMID: 10576185.
10. Monk BJ, Ramp JL, Montz FJ, Lebherz TB. Sacrospinous ligament fixation for vaginal vault prolapse: complications and results. *J Gynecol Surg*. 1991;7(2):87-92. <https://doi.org/10.1089/gyn.1991.7.87>
11. Carey MP, Slack MC. Transvaginal sacrospinous colpopexy for vault and marked uterovaginal prolapse. *Br J Obstet Gynaecol*. 1994 Jun;101(6):536-40. <https://doi.org/10.1111/j.1471-0528.1994.tb13158.x> PubMed PMID: 8018646.

12. Azaïs H, Bassil A, Giraudet G, Rubod C, Lucot JP, Cosson M. How to manage peroperative haemorrhage when vaginally treating genital prolapse. *Eur J Obstet Gynecol Reprod Biol.* 2014 Jul;178:203-7.  
<https://doi.org/10.1016/j.ejogrb.2014.04.023> PubMed PMID: 24813082.